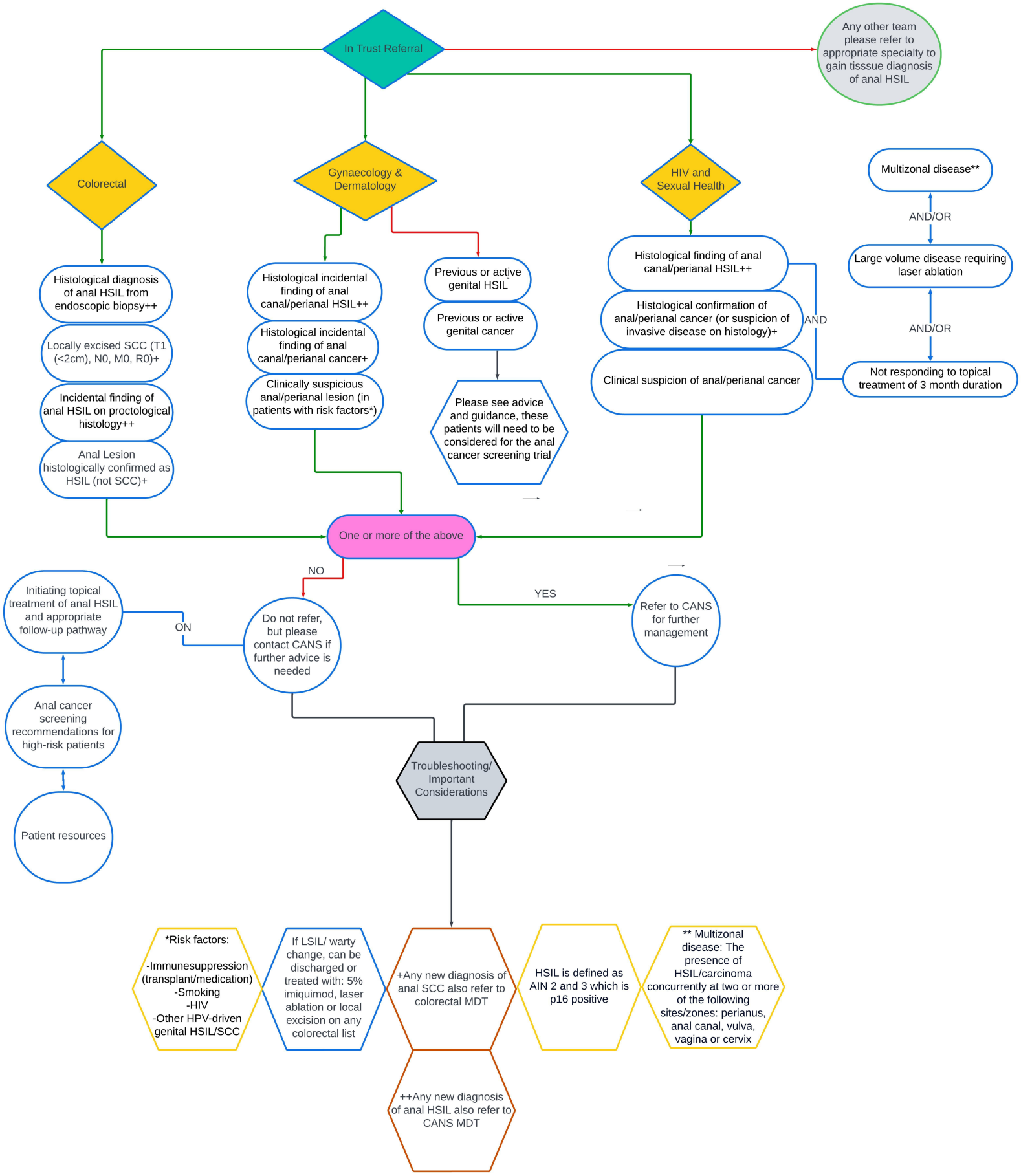
In Trust Referral
Any other team please refer to appropriate specialty to gain tisssue diagnosis of anal HSIL
Colorectal
Gynaecology & Dermatology
HIV and Sexual Health
Multizonal disease**
AND/OR
Large volume disease requiring laser ablation
AND/OR
Not responding to topical treatment of 3 month duration
Histological diagnosis of anal HSIL from endoscopic biopsy++
Locally excised SCC (T1 (<2cm), N0, M0, R0)+
Incidental finding of anal HSIL on proctological histology++
Anal Lesion histologically confirmed as HSIL (not SCC)+
Histological incidental finding of anal canal/perianal HSIL++
Histological incidental finding of anal canal/perianal cancer+
Clinically suspicious anal/perianal lesion (in patients with risk factors*)
Previous or active genital HSIL
Previous or active genital cancer
Please see advice and guidance, these patients will need to be considered for the anal cancer screening trial
Histological finding of anal canal/perianal HSIL++
Histological confirmation of anal/perianal cancer (or suspicion of invasive disease on histology)+
AND
Clinical suspicion of anal/perianal cancer
One or more of the above
NO
YES
Initiating topical treatment of anal HSIL and appropriate follow-up pathway
ON
Do not refer, but please contact CANS if further advice is needed
Refer to CANS for further management
Anal cancer screening recommendations for high-risk patients
Patient resources
Troubleshooting/ Important Considerations
*Risk factors:
-Immunesuppression (transplant/medication)
-Smoking
-HIV
-Other HPV-driven genital HSIL/SCC
If LSIL/ warty change, can be discharged or treated with: 5% imiquimod, laser ablation or local excision on any colorectal list
+Any new diagnosis of anal SCC also refer to colorectal MDT
HSIL is defined as AIN 2 and 3 which is p16 positive
** Multizonal disease: The presence of HSIL/carcinoma concurrently at two or more of the following sites/zones: perianus, anal canal, vulva, vagina or cervix
++Any new diagnosis of anal HSIL also refer to CANS MDT